

Management of isolated anterior talofibular ligament lesion in patients suffering from chronic ankle instability: comparison of two minimally invasive surgical techniques

A. VENTURA¹, C. TERZAGHI², V. MACCHI¹, E. BORGO¹, C. LEGNANI¹

¹IRCCS Istituto Ortopedico Galeazzi, Sport Traumatology and Minimally Invasive Surgery Center, Milan, Italy

²Istituto Clinico Villa Aprica, Como, Italy

Abstract. – OBJECTIVE: The aim of the present study was to retrospectively compare the outcomes of two minimally invasive surgical techniques in patients with isolated anterior talofibular ligament (ATFL) lesion suffering from chronic ankle instability (CAI).

PATIENTS AND METHODS: Thirty-six patients with ATFL lesion suffering from CAI were treated at our department from 2010 to 2017 and retrospectively reviewed after an average time of 4 years (2 to 9 years). Eighteen patients underwent a four-step operative protocol, including: synovectomy, debridement of ATFL lesion borders, capsular shrinkage, and 21-day immobilization and non-weightbearing. Eighteen patients underwent arthroscopic Broström procedure. Patients were assessed pre-operatively and at follow-up with American Orthopedic Foot & Ankle Society Score (AOFAS) scale, Karlsson-Peterson score, Tegner activity level, and objective examination comprehending range of motion, anterior drawer test, and talar tilt test. Wilcoxon test was utilized to compare the pre-operative and follow-up status. The Mann-Whitney U test was used to make comparisons between the two surgical techniques. Statistical significance was established at $p < 0.05$.

RESULTS: Mean overall AOFAS, Karlsson-Peterson and Tegner scores significantly increased at follow-up compared to pre-operative status ($p < 0.05$). However, no statistically significant differences concerning mean AOFAS score (90.2 in the four-step group vs. 89.2 in the Broström arthroscopic group), mean Karlsson-Peterson score (88.1 and 85.9 respectively), and median Tegner activity level (6.0 vs. 5.5) were reported between the two groups ($p = n.s.$). The complications in the arthroscopic four-step treatment group included damage to the superficial branch of the peroneal nerve in one case. The complications in the arthroscopic Broström included nerve injury in one case and persistent local pain nearby suture knot in one case.

CONCLUSIONS: Both arthroscopic Broström and a four-step operative procedure including sy-

novectomy, debridement of ATFL lesion borders, capsular shrinkage and immobilization, improved functional outcomes in patients with ATFL lesion suffering from CAI.

Key Words:

Ankle, Ankle lateral ligaments, Anterior talofibular ligament, Chronic ankle instability, Arthroscopy, Arthroscopic Broström procedure, Thermal shrinkage, Minimally invasive surgery.

Introduction

Ankle sprains are one of the most common musculoskeletal injuries in the general population, with a high incidence among sportsmen. Up to 40% of ankle sprains can lead to persistent pain and giving-way symptoms, a condition known as chronic ankle instability (CAI)^{1,2}.

The anterior talofibular ligament (ATFL) is the most common sprained lateral ligament, and its isolated lesion can be present in up to 80% of patients sustaining an injury³. When conservative treatment fails, ATFL lesion is frequently addressed surgically. Common treatment procedures include direct ligament repair, with or without the use of the inferior extensor retinaculum^{4,7}, or anatomic reconstruction techniques⁸⁻¹⁰.

Arthroscopy is gaining popularity for the treatment of CAI as it reduces morbidity compared to open techniques and allows visualization and treatment of concomitant intra-articular pathologies^{11,12}. Minimally invasive techniques, such as arthroscopic ATFL repair or thermal assisted capsular shrinkage have been proposed to address patients with isolated ATFL lesion suffering from CAI¹³⁻²⁴.

A protocol consisting of 4-step operative procedures aiming to improve the functional outcomes

in patients with ATFL lesion has been implemented in our department. The procedure includes synovectomy, debridement of ATFL lesion borders, capsular shrinkage, and 21-day immobilization and non-weightbearing.

The aim of the present study was to retrospectively compare the outcomes of patients who underwent ATFL repair using Broström arthroscopic procedure with those who were treated according to the 4-step protocol. The hypothesis was that these procedures would provide long-term satisfying functional outcomes and a low rate of recurrence of laxity in patients with isolated ATFL lesion suffering from CAI.

Patients and Methods

Thirty-six patients with isolated ATFL lesion suffering from CAI were treated at our department from 2010 to 2017 and retrospectively reviewed after an average time of 4 years (2 to 9 years). Eighteen consecutive patients (male/female ratio: 11:7) underwent arthroscopic Broström procedure; mean age at surgery was 39.6 years (range 18-60) and mean body mass index (BMI) 25.5 (SD: 8.2).

Patients were matched to a control group of 18 consecutive patients (8 men and 10 women) taken from senior author's database, who underwent a four-step operative procedure, including synovectomy, debridement of ATFL lesion borders, capsular shrinkage, and 21-day immobilization and non-weightbearing. Mean age at surgery was 33.5 years (range 18-49) and mean BMI 24.8 (SD: 7.4). The two groups were comparable for BMI and absence of comorbidities. All operations were performed by a single senior surgeon.

Inclusion criteria were: age 18-55 years, MRI-documented ATFL lesion, positivity to anterior drawer test in plantarflexion compared to contralateral side or anterior drawer test equal or superior to grade 1 according to Nyska et al²⁵. Previous ankle surgery, associated presence of a positive talar tilt test and documented calcaneofibular ligament (CFL) lesion on MRI were considered exclusion criteria.

Surgical Technique of the Four-Step Arthroscopic Technique

Preliminary arthroscopic inspection was performed to assess ligament status and to identify concomitant intraarticular pathologies. Synovectomy was performed to address hypertrophic synovitis. Then, a resection of the borders of the intraar-

ticular part of the ATFL remnants was performed together with a debridement of the adjacent joint capsule. The capsular shrinkage procedure was performed using a VAPR T Side Effect Thermal Electrode (Mitek, Westwood, MA, USA) with a 3.5-mm tip at desiccation mode, a temperature setting of 70°C, and maximum power of 50 W. With the ankle placed in an everted position, the probe was swept from the ATFL and progressing along the adjacent capsule based on visual observation of the macroscopic tissue contraction. At the end of the procedure, portals were closed, and a sterile dressing was applied.

Surgical Technique of Arthroscopic Broström Repair

After preliminary joint inspection, a small third lateral portal was made under arthroscopic control. A Suturefix 1.9-mm double-loaded anchor (Smith & Nephew, Andover, MA, USA) or a 1.4-mm JuggerKnot all-suture anchor (Zimmer Biomet, Warsaw, IN, USA) was then placed at the fibular insertion of the ATFL, with care taken to avoid damaging a branch of the sural nerve and the superficial peroneal nerve. The anchor suture was brought into the ligament stump, the surrounding capsule with a small bird beak through the arthroscopic portal, and the sutures were tied with the ankle joint in a neutral position until optimal tension was reached. After closure of the portals, a sterile dressing was applied.

Rehabilitation Protocol

An identical post-operative protocol was adopted for both groups including the application of an ankle brace (Air-Stirrup, Aircast Inc., Summit, NJ, USA) for the first post-operative 3 weeks without weightbearing. Then, patients were encouraged to gradually regain weightbearing and perform proprioceptive exercises. Return to sports was allowed 12 weeks postoperatively.

Outcome Measures

Clinical assessment included the American Orthopedic Foot and Ankle Society (AOFAS) ankle and hindfoot scoring system, Karlsson-Peterson score, Tegner activity level, and objective examination comprehending range of motion (ROM), anterior drawer and talar tilt test. Postoperative evaluations were performed by the same expert independent observer. All investigations were conducted in conformity with ethical principles of research and in accordance with the guidelines expressed by authors' Institution and with the 1964

Table I. Comparison between pre-operative and follow-up status.

| | Four-step treatment | | | Arthroscopic Broström procedure | | |
|-----------------------------------|---------------------|------------------|-----------------|---------------------------------|------------------|-----------------|
| | Pre-operative | Follow-up | <i>p</i> -value | Pre-operative | Follow-up | <i>p</i> -value |
| AOFAS scale (mean) | 60.4 (SD: 8.8) | 90.2 (SD: 6.8) | <0.05 | 63.8 (SD: 7.6) | 89.2 (SD: 7.7) | <0.05 |
| Karlsson-Peterson score (mean) | 62.5 (SD: 10.1) | 88.1 (SD: 7.4) | <0.05 | 61.3 (SD: 8.4) | 85.9 (SD: 12.5) | <0.05 |
| Tegner score (median) | 4.0 (range 1-6) | 6.0 (range, 3-9) | <0.05 | 3.5 (range 1-5) | 5.5 (range, 3-8) | <0.05 |
| Anterior drawer test (positivity) | 18/18 (100%) | 1/18 (5.5%) | <0.05 | 18/18 (100%) | 1/18 (5.5%) | <0.05 |

AOFAS: American Orthopaedic Foot and Ankle Society; SD: standard deviation.

Helsinki declaration and its later amendments or comparable ethical standards. Informed consent was obtained.

Statistical Analysis

Data extracted were analyzed using IBM SPSS Statistics for Windows® software, Version 21.0 (IBM Corp., Armonk, NY, USA). Shapiro-Wilk test was used for the assessment of normality: it was determined that data did not have a normal distribution. Wilcoxon signed-rank test for related samples was utilized to compare the pre-operative and follow-up status. The Mann-Whitney U test was used to make comparisons between the two surgical techniques. Statistical significance was set at $p < 0.05$.

Results

The median preoperative AOFAS score increased from 60.4 (SD: 8.8) to a postoperative mean value of 90.2 (SD: 6.8) in the four-step group ($p < 0.05$) and from 63.8 (SD: 7.6) to 89.2 (SD: 7.7) in the arthroscopic Broström Group ($p <$

0.05). Similarly, a significant increase was reported at follow-up according to the Karlsson-Peterson score (62.5 to 88.1; $p < 0.05$ and 61.3 to 85.9; $p < 0.05$, respectively) and median Tegner activity level (4.0 to 6.0; $p < 0.05$ and 3.5 to 5.5; $p < 0.05$, respectively). Objective examination at follow-up documented a statistically significant improvement in terms of ankle stability compared to pre-operative manual laxity tests ($p < 0.05$). A detailed overview of the results of clinical assessment is presented in Table I.

No statistically significant differences concerning mean AOFAS score (90.2 in the four-step group vs. 89.2 in the arthroscopic Broström group; $p = \text{n.s.}$), mean Karlsson-Peterson score (88.1 and 85.9 respectively; $p = \text{n.s.}$), and median Tegner activity level (6.0 vs. 5.5; $p = \text{n.s.}$) were reported between the two groups. Complications were reported in 1 (5.5%) and 2 (11.1%) patients who underwent four-step procedure and arthroscopic Broström repair, respectively ($p = \text{n.s.}$) (Figures 1, 2, 3). The complications in the arthroscopic four-step treatment group included damage to the superficial branch of the peroneal nerve in one case. The complications in the arthroscopic Broström included nerve injury in one case and persistent local pain nearby suture knot in another case.

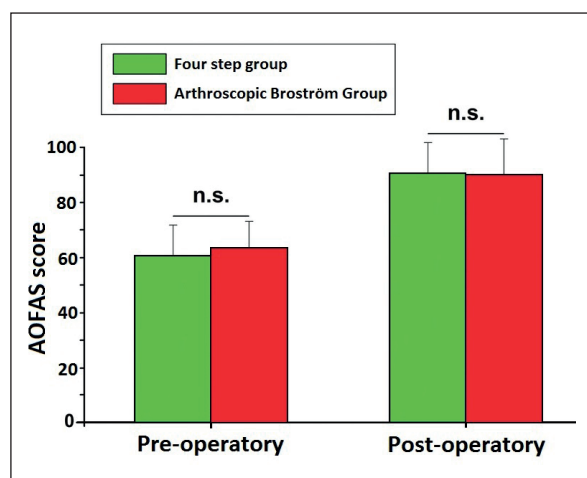


Figure 1. Graph showing the results of the AOFAS score in the two groups.

Discussion

According to our findings both Broström arthroscopic technique and the four-step operative protocol are effective procedures, which improve functional outcomes in patients with ATFL lesion affected by CAI.

According to recent reports, an isolated injury to the intraarticular part of the ATFL is most likely to occur in patients with CAI³. Therefore, patients with isolated ATFL lesion suffering from mild symptoms of instability may benefit from a minimally invasive arthroscopic approach^{11,12}.

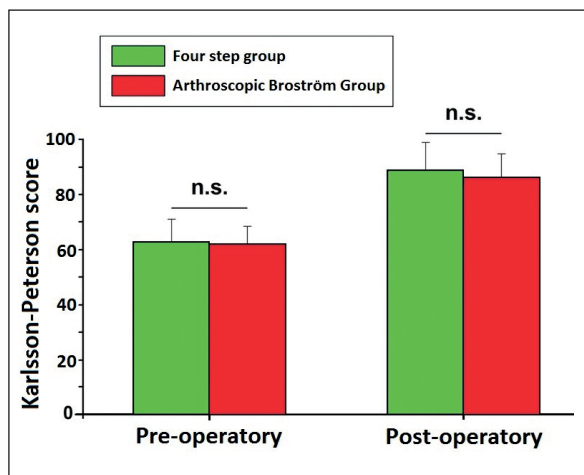


Figure 2. Graph showing the results of the Karlsson-Peterson score in the two groups.

Recently, satisfying postoperative outcomes have been reported following arthroscopic repair of the ATFL^{13,18,22-24}. Cottom et al¹³ reported on 40 patients with CAI that were treated with an all-arthroscopic Broström procedure. At a mean follow-up of 12 months, mean AOFAS, Karlsson-Peterson and VAS score significantly improved compared to pre-operative status. In a comparative study between open vs. arthroscopic Broström-Gould repair, Zeng et al²² reported a significant improvement in AOFAS and Karlsson scores 3 years after surgery, with a mean value of 92.4 and 89.2, respectively. Compared to the arthroscopy group, the open surgery group had significantly shorter duration and lower costs. In their systematic review, Wang et al²³ reported a relatively high complication rate of 17% following arthroscopic repair of the ATFL. Authors described the occurrence of damages to the superficial peroneal or sural nerve and discomfort due to anchor placement or suture knot prominence.

In our case series, the complication rate in the arthroscopic Broström group was 11%, including nerve injury in one case and persistent local pain nearby suture knot in another patient. These complications did not affect the overall surgical outcome.

Concerning arthroscopic thermal shrinkage, previous studies^{14,16,17} demonstrated improvement of symptoms in patients affected by moderate chronic ankle joint laxity. However, controversy exists on the effectiveness of this treatment in the long term, and this procedure has been criticized for its high rate of recurrence of ankle sprains¹⁰. The discrepancy between study outcomes may be related to different inclusion criteria and different postoperative rehabilitation protocols, and at present scientific evidence supporting the long-term ef-

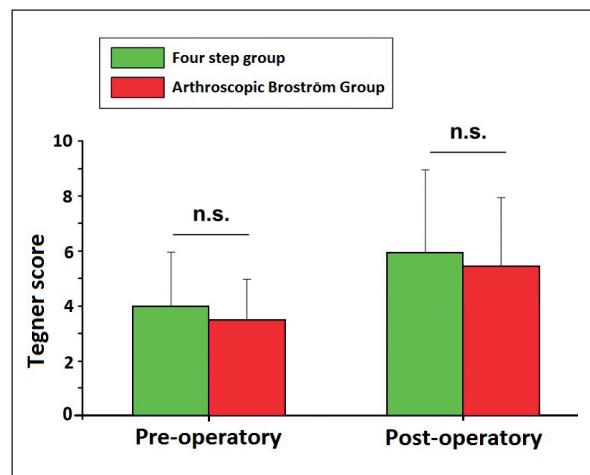


Figure 3. Graph showing the results of the Tegner score in the two groups.

ficacy of thermal shrinkage in restoring ankle laxity is still insufficient to draw firm conclusions²⁶.

Our findings demonstrate that a higher degree of satisfaction was reported in all patients irrespective of the surgical technique adopted. Previous studies^{13,22,23} have shown that the arthroscopic Broström repair possess a good therapeutic efficacy, although it is a technically demanding procedure and carries some risks of postoperative complications. In our case series, a higher complication rate was reported in the arthroscopic Broström group compared to the four-step arthroscopic group, although the results were not statistically significant.

Weaknesses of the present study include its retrospective nature, the relatively small sample size, and the lack of randomization of treatments. Given these limitations, our findings suggest that both techniques constitute a comprehensive approach leading to satisfying outcomes in the treatment of CAI in appropriately selected patients. This information may help the surgeons' approaching patients with isolated ATFL lesion suffering from CAI when choosing between different surgical procedures.

Conclusions

Both arthroscopic Broström and a four-step operative procedure, including synovectomy, debridement of ATFL lesion borders, capsular shrinkage and immobilization, improve functional outcomes in patients with ATFL lesion suffering from CAI.

Conflict of Interest

The authors declare that they have no conflict of interest.

Funding

This research was supported by the Italian Ministry of Health.

References

- 1) Kobayashi T, Koshino Y, Miki T. Abnormalities of foot and ankle alignment in individuals with chronic ankle instability: a systematic review. *BMC Musculoskelet Disord* 2021; 22: 683.
- 2) Ventura A, Legnani C. Chronic ankle instability. In: Volpi P (ed) *Arthroscopy and Sport Injuries. Applications in High-level Athletes*. Springer, Switzerland 2016, 399-404.
- 3) Vega J, Peña F, Golanó P. Minor or occult ankle instability as a cause of anterolateral pain after ankle sprain. *Knee Surg Sports Traumatol Arthrosc* 2016; 24: 1116-1123.
- 4) Broström L. Sprained ankles: VI. Surgical treatment of "chronic" ligament ruptures. *Acta Chir Scand* 1966; 132: 551-565.
- 5) Gould N, Seligson D, Gassman J. Early and late repair of lateral ligament of the ankle. *Foot Ankle* 1980; 1: 84-89.
- 6) Porter DA, Kamman KA. Chronic Lateral Ankle Instability: Open Surgical Management. *Foot Ankle Clin* 2018; 23: 539-554.
- 7) Ventura A, Legnani C, Corradini C, Borgo E. Lateral ligament reconstruction and augmented direct anatomical repair restore ligament laxity in patients suffering from chronic ankle instability up to 15 years from surgery. *Knee Surg Sports Traumatol Arthrosc* 2020; 28: 202-207.
- 8) Brambilla L, Bianchi A, Malerba F, Loppini M, Martinelli N. Lateral ankle ligament anatomic reconstruction for chronic ankle instability: Allograft or autograft? A systematic review. *Foot Ankle Surg* 2020; 26: 85-93.
- 9) Feng SM, Maffulli N, Oliva F, Wang AG, Sun QQ. Arthroscopic Remnant-Preserving Anterior Talofibular Ligament Reconstruction does not Improve Mid-term Function in Chronic Ankle Instability. *Injury* 2020; 51: 1899-1904.
- 10) Vuurberg G, Pereira H, Blankevoort L, van Dijk CN. Anatomic stabilization techniques provide superior results in terms of functional outcome in patients suffering from chronic ankle instability compared to nonanatomic techniques. *Knee Surg Sports Traumatol Arthrosc* 2018; 26: 2183-2195.
- 11) Dalmau-Pastor M, Malagelada F, Calder J, Manzanares MC, Vega J. The lateral ankle ligaments are interconnected: the medial connecting fibres between the anterior talofibular, calcaneofibular and posterior talofibular ligaments. *Knee Surg Sports Traumatol Arthrosc* 2020; 28: 34-39.
- 12) Legnani C, Borgo E, Macchi V, Ventura A. Does the Association of Microfractures for the Treatment of Osteochondral Lesions of the Talus Affect the Outcome Following Arthroscopic Treatment for Chronic Ankle Instability? *J Am Podiatr Med Assoc* 2021; 111: Article 3.
- 13] Cottom JM, Rigby RB. The "all inside" arthroscopic patients. *J Foot Ankle Surg* 2013; 52: 568-574.
- 14) de Vries JS, Krips R, Blankevoort L, Fievez AW, van Dijk CN. Arthroscopic capsular shrinkage for chronic ankle instability with thermal radiofrequency: prospective multicenter trial. *Orthopedics* 2008; 31: 655.
- 15) Guelfi M, Vega J, Malagelada F, Dalmau-Pastor M. The arthroscopic all-inside ankle lateral collateral ligament repair is a safe and reproducible technique. *Knee Surg Sports Traumatol Arthrosc* 2020; 28: 63-69.
- 16) Ventura A, Borgo E, Terzaghi C, Macchi V, Legnani C. A four-step approach improves long-term functional outcomes in patients suffering from chronic ankle instability: a retrospective study with a follow-up of 7-16 years. *Knee Surg Sports Traumatol Arthrosc* 2021; 29: 1612-1616.
- 17) Maiotti M, Massoni C, Tarantino U. The use of arthroscopic thermal shrinkage to treat chronic lateral ankle instability in young athletes. *Arthroscopy* 2005; 21: 751-757.
- 18) Allegra F, Boustany SE, Cerza F, Spiezia F, Maffulli N. Arthroscopic anterior talofibular ligament reconstruction in chronic ankle instability: Two years results. *Injury* 2020; 51 Suppl 3: S56-S62.
- 19) Vega J, Guelfi M, Malagelada F, Peña F, Dalmau-Pastor M. Arthroscopic All-Inside Anterior Talofibular Ligament Repair Through a Three-Portal and No-Ankle-Distraction Technique. *JBJS Essential Surg Tech* 2018; 8: e25.
- 20) Ventura A, Terzaghi C, Legnani C, Borgo E. Arthroscopic four-step treatment for chronic ankle instability. *Foot Ankle Int* 2012; 33: 29-36.
- 21) Ventura A, Terzaghi C, Legnani C, Borgo E. Treatment of post-traumatic osteochondral lesions of the talus: a four-step approach. *Knee Surg Sports Traumatol Arthrosc* 2013; 21: 1245-1250.
- 22) Zeng G, Hu X, Liu W, Qiu X, Yang T, Li C, Song W. Open Broström-Gould Repair vs Arthroscopic Anatomical Repair of the Anterior Talofibular Ligament for Chronic Lateral Ankle Instability. *Foot Ankle Int* 2020; 41: 44-49.
- 23) Wang J, Hua Y, Chen S, Li H, Zhang J, Li Y. Arthroscopic repair of lateral ankle ligament complex by suture anchor. *Arthroscopy* 2014; 30: 766-773.
- 24) Zhou YF, Zhang ZZ, Zhang HZ, Li WP, Shen HY, Song B. All-Inside Arthroscopic Modified Broström Technique to Repair Anterior Talofibular Ligament Provides a Similar Outcome Compared With Open Broström-Gould Procedure. *Arthroscopy* 2021; 37: 268-279.
- 25) Nyska M, Amir H, Porath A, Dekel S. Radiological assessment of a modified anterior drawer test of the ankle. *Foot Ankle* 1992; 13: 400-403.
- 26) Yasui Y, Murawski CD, Wollstein A, Takao M, Kennedy JG. Operative Treatment of Lateral Ankle Instability. *JBJS Rev* 2016; 31; 4: e6.