

Age and gender related changes in bronchial tree: a morphometric study with multidetector CT

M. ULUSOY¹, I.I. UYSAL², A.S. KIVRAK³, S. OZBEK³, A.K. KARABULUT², Y. PAKSOY³, N.U. DOGAN²

¹Department of Anatomy, Mevlana University Medical Faculty, Konya, Turkey

²Department of Anatomy, Selcuk University Medical Faculty, Konya, Turkey

³Department of Radiology, Selcuk University Medical Faculty, Konya, Turkey

Abstract. – OBJECTIVE: The aims of this study are the identification of differences in the diameter, length, area and branching angles of the trachea and bronchi with gender and age, and the identification of trachea types by using MDCT images.

PATIENTS AND METHODS: The thoracic MDCT images of 253 patients (0-74 years old, 142 male and 111 female) were evaluated. Tracheal diameter, tracheal cross-sectional area, diameter and length of bronchi, and several angles of the bronchial tree [e.g. subcarinal angles (SCA), interbronchial angles (IBA)] were measured.

RESULTS: Average anteroposterior and transverse diameter of the trachea in adult patients were measured as 15.8 ± 2.9 mm and 17.5 ± 3.7 mm respectively. Average tracheal cross-sectional areas in adult patients were calculated as 160.7 ± 41.3 mm² in females and as 275.7 ± 57.3 mm² in males. Four types of trachea were identified as circular (68% in adults, 73% in children), oval (13%, 15%), rectangular (11%, 5%) and horseshoe shaped (8%, 7%). The average right and left SCA were calculated as $34.5^\circ \pm 8.1^\circ$ and $38.1^\circ \pm 8.9^\circ$ respectively. The average right and left IBA were calculated as $32.4^\circ \pm 7.7^\circ$ and $35.2^\circ \pm 8.1^\circ$ respectively.

CONCLUSIONS: The findings of this study may be helpful during bronchoscopy and tube and stent application procedures. MDCT seems to be a convenient technique for the evaluation of the bronchial tree.

Key Words

Bronchial tree, Multidetector CT, Tracheal type, Morphometry.

been evaluated by several techniques including posteroanterior chest radiography, bronchoscopy, bronchography, computed tomography and multidetector computed tomography (MDCT)^{2,3}.

MDCT is a new form of computed tomography technology for diagnostic imaging. It provides the improved quality of two-dimensional multiplanar and three-dimensional reconstruction images^{4,5}. With image reconstruction, mediastinal and hilar structures, pulmonary and systemic vascularity and bronchial structures can be imaged in axial, coronal and sagittal planes^{6,7}. Three-dimensional reconstruction provides better diagnostic thoracic imaging^{8,9}. It was reported that disease of the bronchial tree could be best diagnosed by MDCT^{10,11}.

It is important to know diameter, length and branching angles of airways for safe and successful applications of bronchoscopy and double lumen tube (DLT) application. Bronchoscopy is another important diagnostic and therapeutic technique in routine use^{12,13}. DLT is used for the one lung ventilation in thoracic anesthesia^{14,15}.

The aims of this study are the identification of differences in diameter, length, area and branching angles of trachea and bronchi with gender and age; and identification of trachea types by using MDCT images. The findings of this work will help clinicians in applications such as bronchoscopy and DLT.

Patients and Methods

This study was approved by the local Ethic Committee with approval number 2009/343. Thoracic MDCT (Toshiba, Aquilion super 4, Japan) images of 253 patients (0-74 years old, 142 male

Introduction

Bronchial tree constitutes an important part of the respiratory system¹. It is affected by many diseases which have similar symptoms. It has

and 111 female) were evaluated. These patients had no detected pathology. Patients were grouped according to age as 0-18 years-old, 19-37 years old, 38-56 years old and 57-74 years old. Beside these patients were also grouped as children (0-18 years old) and adults for some parameters.

Axial CT images with a slice thickness of 3 mm were transferred to a separate workstation for three-dimensional reconstructions. The measurements of the central airways were made by the same person.

Tracheal diameter, tracheal cross-sectional area, diameter and length of right and left main bronchus, right and left lobar bronchus and branching angle of lobar bronchi from their main bronchus and branching angle of lobar bronchi between each other were measured^{16,17} (Figure 1). Beside, angles between an imaginary line passing through the middle of the lumen of the main bronchi and an imaginary line passing through the middle of the lumen of the lobar bronchi were measured^{17,18} (Figure 2).

Anteroposterior and transverse diameter of the trachea were measured in a slice 10 mm above the carina from axial images^{19,20}. To standardize identification of trachea types, the ratio of the anteroposterior diameter (a) to the transverse diameter (b) was calculated. With this ratio, four types of trachea were identified as circular ($a / b = 1 \pm 0.2$ mm), oval ($a / b < 1 \pm 0.2$ mm), horse-shoe-shaped ($a / b > 1 \pm 0.2$ mm) and rectangular ($a / b = 1 / 2 \pm 0.2$ mm). Beside tracheal cross-sectional area was calculated from the same slice.

In coronal images, a vertical line passing through the middle of the carina (tracheal axis) was drawn. Angles between tracheal axis and inferior outer edge of right and left main bronchus [right and left subcarinal angles (SCA)] and angles between tracheal axis and imaginary lines passing through the middle of the lumen of the right and left main bronchus [right and left inter-bronchial angles (IBA)] were measured^{17,18,21}.

Beside diameter and length of right main bronchus, right upper lobe bronchus, bronchus

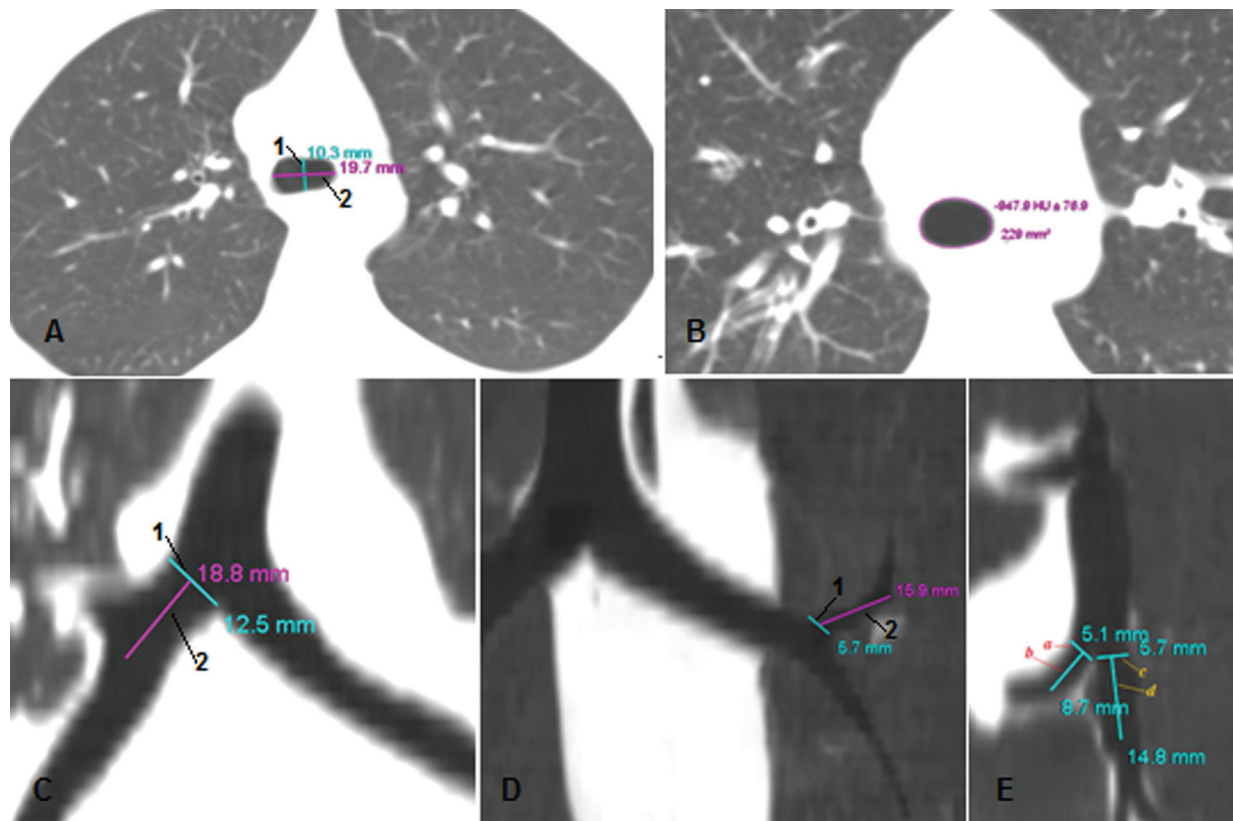


Figure 1. Measurement of anteroposterior (1) and transverse (2) diameter of the trachea (A) and tracheal cross-sectional area (B) in axial plane. Measurement of diameter (1) and length (2) of right main bronchus (C) and left upper lobe bronchus (D) in coronal plane. Measurement of diameter (a) and length (b) of middle lobe bronchus and diameter (c) and length (d) of right lower lobe bronchus in sagittal plane (E).

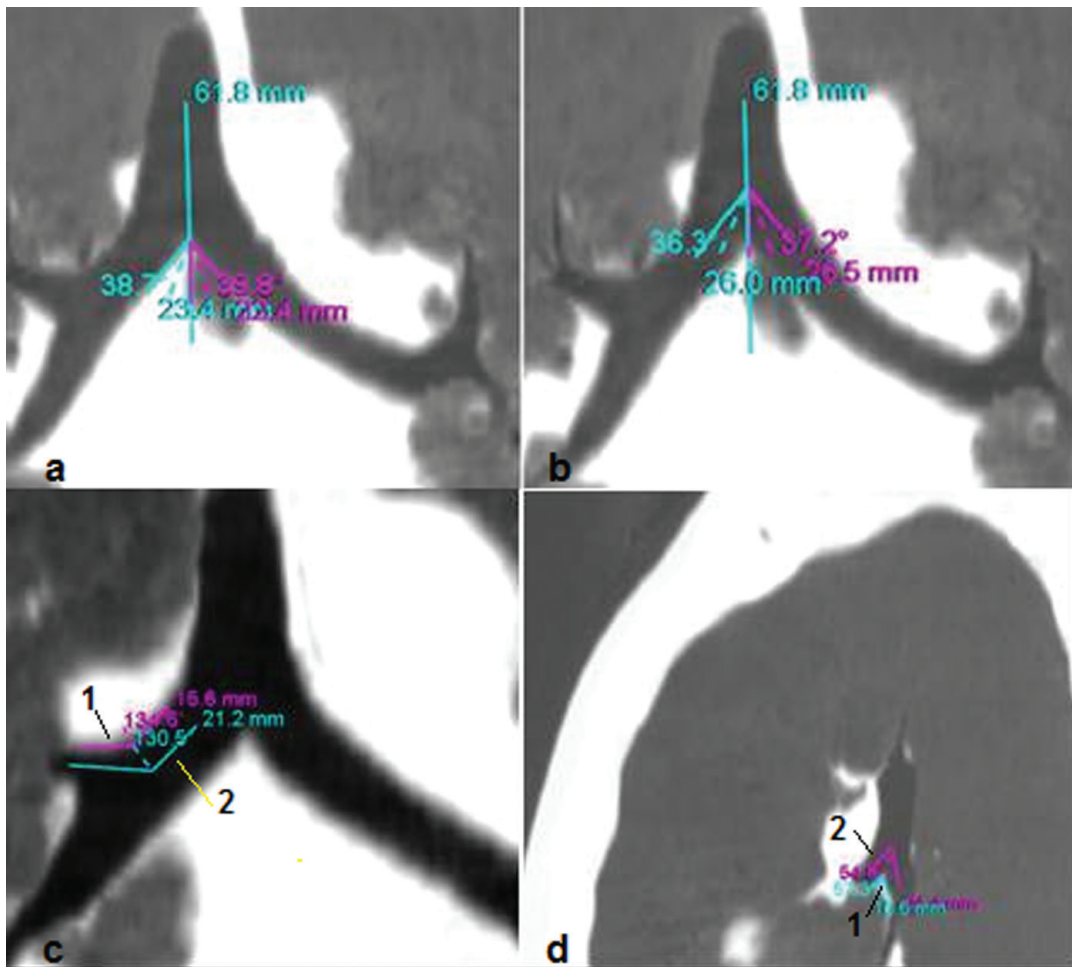


Figure 2 Measurement of right and left subcarinal angle (a), right and left interbronchial angle (b), and external (1) and internal (2) angle between right upper lobe bronchus and right main bronchus (c) in coronal plane. Measurement of external (1) and internal (2) angle between left main bronchus and left lower lobe bronchus in sagittal plane.

intermedius, left main bronchus, left upper lobe bronchus and left lower lobe bronchus were measured^{17,21,22}.

The diameter of bronchus was identified as the distance between its lateral and medial walls. The length of bronchus was identified as the distance between the beginning of bronchus and level of its first branch. In coronal images external and internal angles between main and a lobar bronchus were measured. External angle was identified as the angle between external walls of bronchus whereas internal angle was identified as the angle between an imaginary lines passing through lumen of bronchus.

Because of their anatomic location, middle lobar bronchus and right lower lobe bronchus cannot be evaluated accurately in coronal plane. Therefore, they were evaluated in sagittal plane

images. Diameter and length of these bronchi and external and internal angles between these bronchi were measured (Figure 2).

Statistical Analysis

The distribution of continuous variables was examined for normality. Descriptive statistics (mean and standard deviation (SD), and percentage) were used to summarize the data. All data is normally distributed. Student's *t*-test was used for comparing means of two groups and one-way analysis of variance (ANOVA) was used comparing means of more groups. Significant differences were evaluated by post hoc testing (Tukey's honestly significant difference). Statistical significance was defined as a *p*-value of less than 0.05. Statistical software (SPSS for Windows, release 11.0; SPSS, Chicago, IL, USA) was used.

Table I. Average measures of trachea diameter according to gender and age groups.

Parameter	Gender	0-18 years (mean \pm SD) [mm]	19-37 years (mean \pm SD) [mm]	38-56 years (mean \pm SD) [mm]	57-74 years (mean \pm SD) [mm]
Anteroposterior diameter [mm]	Female	9.4 \pm 3.2 (n:15)	12.9 \pm 1.7 (n:27)	13.8 \pm 1.9 (n:49)	13.3 \pm 2.4 (n:20)
	Male	12.2 \pm 3.0 (n:26)	16.8 \pm 1.7 (n:44)	18.4 \pm 2.3 (n:50)	17.9 \pm 2.1 (n:22)
Transversal diameter [mm]	Female	9.9 \pm 3.0 (n:15)	15.6 \pm 2.9 (n:27)	15.3 \pm 2.6 (n:49)	13.9 \pm 2.2 (n:20)
	Male	13.7 \pm 3.9 (n:26)	19.2 \pm 3.2 (n:44)	19.7 \pm 2.9 (n:50)	19.0 \pm 4.1 (n:22)

Results

All MDCT images were performed in The Department of Radiology at The Selcuk University Hospital between January 2011 and December 2011. These images were reviewed retrospectively.

Tracheal Findings

Average anteroposterior and transverse diameter of the trachea in patients were measured as 15.8 \pm 2.9 mm and 17.5 \pm 3.7 mm respectively from slices obtained 1 cm above the carina. Average values of tracheal diameters according to gender and age groups were shown in Table I.

According to a proportional formula obtained from anteroposterior and transverse diameter of the trachea of 253 patients in this work, four types of trachea were identified. These are circular (68%, n: 170), oval (13%, n: 34), rectangular (11%, n: 29) and horseshoe shape (8%, n: 20) in adult patients; and circular (73%, n: 30), oval (15%, n: 6), rectangular (5%, n: 2) and horseshoe shape (7%, n: 3) in child patients. Types of trachea according to gender and age groups were shown in Table II.

Average tracheal cross-sectional areas in adult patients were calculated as 160.7 \pm 41.3 mm² in females and 275.7 \pm 57.3 mm² in males. Average values of tracheal cross-sectional area according to gender and age groups were shown in Table III.

Bronchial Findings

Average right and left SCA were calculated as 34.5° \pm 8.1° and 38.1° \pm 8.9° respectively. Average right and left IBA were calculated as 32.4° \pm 7.7° degree and 35.2° \pm 8.1° respectively. Average right and left SCA were greater in females than in males, although not significant, in each age group except 0-18 years old age group (Table IV).

Average external and internal angle between right main bronchus and right upper lobe bronchus were calculated as 121.5° \pm 12.5° and 118.3° \pm 12.8° respectively. Average external and internal angle between right upper lobe bronchus and intermediate bronchus were calculated as 86.8° \pm 16.3° and 81.0° \pm 12.6° respectively. Average external and internal angle between middle lobar bronchus and right lower lobe bronchus were calculated as 47.1° \pm 13.9° and 45.1° \pm 13.5° respectively. Angles of right main bronchus were greater in females ($p < 0.05$).

Table II. Trachea types according to gender and age groups.

Parameter	Gender	0-18 years (Female n:15, Male n:26)	19-37 years (Female n:27, Male n:44)	38-56 years (Female n:49, Male n:50)	57-74 years (Female n:20 Male n:22)	<i>p</i>
Round	Female	73% (n:11)	56% (n:15)	70% (n:34)	65% (n:13)	<i>p</i> < 0.05
	Male	73% (n:19)	70% (n:31)	72% (n:36)	50% (n:11)	
Oval	Female	20% (n:3)	5% (n:7)	18% (n:9)	5% (n:1)	
	Male	11% (n:3)	12% (n:5)	8% (n:4)	9% (n:2)	
Square	Female	0% (n:0)	18% (n:5)	10% (n:5)	15% (n:3)	
	Male	8% (n:2)	16% (n:7)	8% (n:4)	14% (n:3)	
Horseshoe	Female	7% (n:1)	0% (n:0)	2% (n:1)	15% (n:3)	
	Male	8% (n:2)	2% (n:1)	12% (n:6)	27% (n:6)	

Table III. Average measures of trachea cross-sectional area according to gender and age groups.

Parameter	Gender	0-18 years (mean \pm SD) [mm ²]	19-37 years (mean \pm SD) [mm ²]	38-56 years (mean \pm SD) [mm ²]	57-74 years (mean \pm SD) [mm ²]	<i>p</i>
Tracheal cross- sectional area [mm ²]	Female	78.4 \pm 44.3 (n: 15)	157.1 \pm 39.5 (n: 27)	169.1 \pm 42.1 (n: 49)	145.2 \pm 38.2 (n: 20)	<i>p</i> < 0.01
	Male	138.5 \pm 63.8 (n: 26)	261.9 \pm 54.8 (n: 44)	282.4 \pm 66.5 (n: 50)	275.2 \pm 61.1 (n: 22)	

Average diameter and length of right main bronchus in adult patients were calculated as 13.4 \pm 2.0 mm and 24.7 \pm 4.8 mm respectively. Average diameter and length of right upper lobe bronchus in adult patients were calculated as 10.0 \pm 2.2 mm and 12.5 \pm 2.8 mm respectively. Average diameter and length of intermediate bronchus in adult patients were calculated as 12.0 \pm 1.7 mm and 24.1 \pm 5.9 mm respectively. Average diameter and length of middle lobar bronchus were calculated as in adult patients 5.4 \pm 1.2 mm and 9.5 \pm 3.2 mm respectively. Average diameter and length of right lower lobe bronchus were calculated as in adult patients 6.4 \pm 1.6 mm and 11.3 \pm 4.3 mm respectively. Average external and internal angle between left main bronchus and left upper lobe bronchus were calculated as 142.2° \pm 11.2° and 140.6° \pm 11.4° respectively. Average external and internal angle between left upper lobe bronchus and left lower lobe bronchus were calculated as 58.7° \pm 16.7° and 56.2° \pm 15.4° respectively.

Average diameter and length of left main bronchus in adult patients were calculated as 11.0 \pm 1.9 mm and 51.7 \pm 7.8 mm respectively. Its average diameter is greater in 38-56 years old age group whereas its average length is greater in 19-37 years

old age group. Average diameter and length of left upper lobe bronchus in adult patients were calculated as 8.6 \pm 1.7 mm and 12.3 \pm 3.6 mm respectively. Average diameter and length of left lower lobe bronchus in adult patients were calculated as 7.7 \pm 1.8 mm and 18.7 \pm 6.8 mm respectively.

Discussion

Most of the morphometric studies associated with bronchial tree have been done by only the posteroanterior chest radiography. There are several studies measuring diameter, length and angles of the trachea and main bronchi in different levels and planes by computed tomography^{18,21}. And there is only one morphometric study evaluating bronchial tree by MDCT¹⁶.

Oliver et al¹⁶ had measured transverse and anteroposterior diameters of the trachea from thoracic CT images of 101 male and 105 female patients to evaluate the relation between measured diameters of trachea and weight and height of patients for choosing the appropriate size of DLT. They measured the diameters at the midclavicular level in the axial plane. They found transverse and anteropos-

Table IV. Average measures of subcarinal angle according to gender and age groups.

Parameter	Gender	0-18 years (mean \pm SD) (Female n:15, Male n:26)°	19-37 years (mean \pm SD) (Female n:27, Male n:44)°	38-56 years (mean \pm SD) (Female n:49, Male n:50)°	57-74 years (mean \pm SD) (Female n:20 Male n:22)°
SA1	Female	31.9 \pm 8.5	32.6 \pm 7.1	36.8 \pm 7.4	39.0 \pm 7.3
	Male	35.3 \pm 7.7	32.3 \pm 9.1 ^a	34.1 \pm 8.1	33.8 \pm 8.0
SA2	Female	37.7 \pm 6.5	37.3 \pm 9.3	40.9 \pm 7.4	43.4 \pm 8.8
	Male	37.2 \pm 8.8	35.0 \pm 9.0	38.1 \pm 9.3	34.7 \pm 9.2
IBA1	Female	29.6 \pm 8.0	31.2 \pm 6.8	34.6 \pm 6.8	35.9 \pm 7.4
	Male	33.1 \pm 6.0	30.0 \pm 8.1	32.7 \pm 8.6	31.0 \pm 7.6
IBA2	Female	34.5 \pm 6.5	33.8 \pm 8.8	38.1 \pm 7.1	39.5 \pm 8.1
	Male	35.2 \pm 6.7	32.2 \pm 8.0 ^a	35.5 \pm 8.4	31.8 \pm 8.7

SA1: Right subcarinal angle; SA2: Left subcarinal angle; IBA1: Right interbronchial angle; IBA2: Left interbronchial angle; SD: Standard Deviation; °: Angle.

terior diameter of the trachea as 17.1 ± 3.6 mm and 19.7 ± 3.7 mm respectively in males; and 15.7 ± 2.1 mm and 16.0 ± 2.2 mm respectively in females. In that study anteroposterior diameter of trachea was greater than the transverse diameter although this difference was significant only in males. Whereas in our study the transverse diameter of the trachea was greater than the anteroposterior diameter, although not significant. This discrepancy can be due to level of measurements since in our study measurements were made at 10 mm above the carina in axial plane; or due to patients population. Oliver et al¹⁶ could not propose a proportion between the diameter measurements and height and weight of patients for choosing appropriate size of DLT. Beside, the relation between anteroposterior and transverse diameter can be important for choosing appropriate size of DLT. Considering findings of our and Oliver et al¹⁶, it is necessary to make further researches in larger populations.

It was reported that intrathoracic trachea is usually circular or oval, and sometimes is rectangular or horseshoe shape; and its shape can change according to its level^{19,20}. Gamsu and Webb¹⁹ had reported from thoracic CT images that trachea has different shape in 22 out of 50 patients. 12 patients (24%) have horseshoe shape trachea, 6 patients (12%) have inverted pear shaped trachea and 2 (4%) patients have rectangular trachea. These findings agree with our findings. In our study, trachea types were determined according to ratio of its anteroposterior diameter to its transverse diameter. Although there is no other investigation performing proportional type determination of the trachea in literature, it seems that proportional type determination is convenient method according to our findings and the findings of Gamsu and Webb¹⁹.

Vock et al²³ had measured tracheal slice area at the level of intrathoracic inlet, middle of trachea and subcarina from CT images of 25 male and 25 female patients. They reported average tracheal slice area as 272 mm² in male and 194 mm² in female. For male patients these findings are agree with ours, but for female patients it seems that there is important difference between the two researches. In our study, measurements were made only at 10 mm above the carina. It seems that measurement at only one level is not confident.

Previously¹⁵⁻¹⁷, SCA and IBA were measured as single i.e. they were not divided as left and right. We divided SCA and IBA at an imaginary vertical line passing through middle of carina to right and left SCA and IBA to supply more data

for safer entry to bronchi during bronchoscopy. Karabulut²¹ reported average SCA as $70 \pm 16^\circ$ in males and $77 \pm 14^\circ$ in females; Kamel et al¹⁸ reported average SCA as $76 \pm 20^\circ$ in males and $81 \pm 20^\circ$ in females. Taken right and left SCA together, our findings (SCA is approximately 72° in males and 76° in females) are in agreement with the findings of Karabulut²¹ and Kamel et al¹⁸. Also, in these reports and our study, SCA is greater in females than in males. Karabulut²¹ reported average IBA as $75 \pm 13^\circ$ in males and $81 \pm 12^\circ$ in females. Taken right and left IBA together our IBA values (approximately 66° in males and 70° in females) are somewhat lower than that of Karabulut et al²¹. However in both study IBA is greater in females than in males. Considering all of these findings MDCT seems to be confident technique for measuring SCA and IBA.

Conclusions

In this present study, diameter, length and angle values of bronchial tree according to age and gender were obtained. These values can be helpful during bronchoscopy and tube and stent application procedures. Also considering findings of our and other researches, MDCT seems to be a convenient technique for morphologic evaluation of the bronchial tree.

Conflict of Interests

The Authors declare that they have no conflict of interests.

References

- 1) HYDE DM, HAMID O, IRVIN CG. Anatomy, pathology, and physiology of the tracheobronchial tree: Emphasis on the distal airways. *J Allergy Clin Immunol* 2009; 124: 7-72.
- 2) JAVIDAN-NEJAD C. MDCT of trachea and main bronchi. *Radiol Clin North Am* 2010; 48: 157-176.
- 3) BOISELLE PM, LYNCH DA. Anatomical airway imaging methods. In: Boisselle PM, Lynch DA, editors. *CT of the airways*. Humana Press 2008; 75-94.
- 4) LAWLER LP, FISHMAN EK. Multi-detector row CT of thoracic disease with emphasis on 3D volume rendering and CT angiography. *Radiographics* 2001; 21: 1257-1273.
- 5) RAVENEL JG, McADAMS HP, REMY-JARDIN M, REMY J. Multidimensional imaging of the thorax: practical applications. *J Thorac Imaging* 2001; 16: 269-281.
- 6) SUSSMANN AR. Understanding chest radiographic anatomy with MDCT reformations. *Clin Radiol* 2010; 65: 155-166.

- 7) BOISELLE PM, ERNST A. Recent advances in central airway imaging. *Chest* 2002; 121: 1651-1660.
- 8) KIRALY AP, HIGGINS WE, McLENNAN G, HOFFMAN EA, REINHARDT JM. Three-dimensional human airway segmentation methods for clinical virtual bronchoscopy. *Acad Radiol* 2002; 9: 1153-1168.
- 9) LAROIA AT, THOMPSON BH, LAROIA ST, VAN BEEK EJR. Modern imaging of the tracheo-bronchial tree. *World J Radiol* 2010; 2: 237-248.
- 10) BEIGELMAN-AUBRY C, BRILLET P-Y, GRENIER PA. MDCT of the airways: Technique and normal results. *Radiol Clin North Am* 2009; 47: 185-201.
- 11) DIALANI V, ERNST A, SUN M, LEE KS, FELLER-KOPMAN D, LITMANOVICH D, BANKIER A, BOISELLE PM. MDCT detection of airway stent complications: comparison with bronchoscopy. *AJR Am J Roentgenol* 2008; 191: 1576-1580.
- 12) WAHIDI MM, HERTH FJ, ERNST A. State of the art: interventional pulmonology. *Chest* 2007; 131: 261-274.
- 13) YONKER LM, FRACCHIA MS. Flexible bronchoscopy. *Adv Otorhinolaryngol* 2012; 73: 8-12.
- 14) HANNALLAH M, BENUMOF JL, SILVERMAN PM, KELLY LC, LEA D: Evaluation of an approach to choosing a left double-lumen tube size based on chest computed tomographic scan measurement of left mainstem bronchial diameter. *J Cardiothorac Vasc Anesth* 1997; 11: 168-171.
- 15) CHOW MY, LIAM BL, THNG CH, CHONG BK. Predicting the size of a double-lumen endobronchial tube using computed tomographic scan measurements of the left main bronchus diameter. *Anesth Analg* 1999; 88: 302-305.
- 16) OLIVIER P, HAYON-SONSINO D, CONVARD JP, LALOË PA, FISCHLER M. Measurement of left mainstem bronchus using multiplane CT Reconstructions and relationship between patient characteristics or tracheal diameters and left bronchial diameters. *Chest* 2006; 130: 101-107.
- 17) KILIÇ C, KIRICI Y, OZAN H. Morphometrically assessment of the bronchial tree. *Turkiye Klinikleri Arch Lung* 2009; 10: 45-50.
- 18) KAMEL KS, LAU G, STRINGER MD. In Vivo and In Vitro morphometry of the human trachea. *Clin Anat* 2009; 22: 571-579.
- 19) GAMSU G, WEBB WR. Computed tomography of trachea: normal and abnormal. *AJR Am J Roentgenol* 1982; 139: 321-326.
- 20) NAIDICH DP, WEBB WR, MÜLLER NL, KRINSKY GA, ZERHOUNI EA, SIEGELMA SS, EDS. *Computed Tomography and Magnetic Resonance of the Thorax*. 3rd ed. Philadelphia: Lippincott Williams & Wilkins, 1999; pp. 176-194.
- 21) KARABULUT N. CT assessment of tracheal carinal angle and its determinants. *Br J Radiol* 2005; 78: 787-790.
- 22) MONTAUDON M, DESBARATS P, BERGER P, DE DIETRICH G, MARTHAN R, LAURENT F. Assessment of bronchial wall thickness and lumen diameter in human adults using multi-detector computed tomography: Comparison with theoretical models. *J Anat* 2007; 211: 579-588.
- 23) VOCK P, SPIEGEL T, FRAM EK, EFMANN EL. CT Assessment of the Adult Intrathoracic Cross Section of Trachea. *J Comput Assist Tomogr* 1984; 8: 1076-1082.