

# Clinical effectiveness of a new oral curcumin formulation in acute non-infectious uveitic macular edema: a 12-month observational study

P. ALLEGRI<sup>1</sup>, R. ROSA<sup>2</sup>, A. MASALA<sup>3</sup>, R. RISSOTTO<sup>4</sup>, F. RISSOTTO<sup>5</sup>, M.G. CRIVELLI<sup>6</sup>, S. PERI<sup>6</sup>

<sup>1</sup>Inflammatory Eye Diseases Referral Center, Rapallo Hospital, Genoa, Italy

<sup>2</sup>University Eye Clinic of Genova, Genova, Italy

<sup>3</sup>Ophthalmological Department of Genova Local Health Authority No. 3, Genoa, Italy

<sup>4</sup>University Eye Clinic of Milano, San Paolo Hospital, Milan, Italy

<sup>5</sup>University Eye Clinic of Pisa, Pisa, Italy

<sup>6</sup>Pharmaceutical Department of Genova Local Health Authority No. 4, Genoa, Italy

**Abstract. – OBJECTIVE:** Oral supplementation with curcumin demonstrated a beneficial effect on some ocular diseases, including uveitis and macular edema. This study aimed to evaluate the effectiveness and safety of a curcumin formulation with the hydrophilic carrier (CHC; Diabec®, Alfa Intes, Italy) as an adjuvant to standard steroid treatment in adults suffering from acute non-infectious uveitic macular edema (NIUME).

**PATIENTS AND METHODS:** This was a mono-center prospective observational study carried out between January 2019 and May 2020 on consecutive patients with a new diagnosis of NIUME. Patients were treated with standard therapy or with a CHC add-on to standard treatment. The observation period for each patient was 12 months. The Best Corrected Visual Acuity (BCVA) and the Central Macular Thickness (CMT) were the primary outcomes; Foveal Avascular Zone (FAZ) and intraocular pressure (IOP) were also assessed, along with safety data.

**RESULTS:** A total of 43 eyes of 26 patients were analyzed. CHC-treated eyes showed an improvement in mean BCVA from baseline (0.34 logMar) to T<sub>6</sub> (0.20 logMar) and T<sub>12</sub> (0.19 logMar;  $p \leq 0.05$  and  $p \leq 0.01$ , respectively); CMT decreased from a mean of 320  $\mu\text{m}$  (T<sub>0</sub>) to 278  $\mu\text{m}$  (T<sub>6</sub>;  $p \leq 0.05$ ) and 272  $\mu\text{m}$  (T<sub>12</sub>;  $p \leq 0.01$ ). A significant improvement of mean BCVA in the CHC group at T<sub>6</sub> and T<sub>12</sub> was reported compared to the control group ( $p \leq 0.01$ ). FAZ and IOP showed no statistically significant variations in both groups. No adverse events were recorded.

**CONCLUSIONS:** CHC as an adjuvant treatment improved the anatomical and functional outcomes, without significant side effects in eyes affected by the recent onset of NIUME, compared to the sole standard therapy.

## Key Words:

Non-infectious uveitic macular edema (NIUME), High bioavailable curcumin (CHC), CurcuWIN, BCVA, SD-OCT, angio-OCT.

## Introduction

Macular edema (ME) is the most common sight-threatening complication of uveitis (UME), and it has been reported in 1/3 of uveitis patients<sup>1</sup>. UME can be seen in infectious and non-infectious conditions (NIUME) and is associated with autoimmune diseases (mainly sarcoidosis, multiple sclerosis, rheumatoid syndromes and Behçet's disease).

To treat NIUME, different drugs (from topical NSAIDs and/or local, sub-tenon and short- or long-acting intravitreal steroids to systemic drugs, such as steroids, immunosuppressants and biologics) have been proposed, but most, if not all, have significant potential for causing local or systemic adverse events (for instance, cataract and intraocular pressure (IOP) for local steroids, or more significant systemic reactions from drugs, such as IFN- $\alpha$ )<sup>2-4</sup>. In addition, ME may persist, leading to permanent photoreceptor damage and loss of central vision<sup>5-7</sup>. Consequently, new strategies are needed to improve available anti-edema therapies, particularly as regards the safety profile.

Curcumin, an active derivative from Curcuma Longa rhizome, has shown its scavenger potential against reactive oxygen molecules in many studies<sup>8,9</sup>, making it an antioxidant and anti-in-

flammatory product. Nevertheless, curcumin is a molecule with poor systemic and ocular tissues bioavailability due to its low water solubility, rapid systemic metabolism and elimination<sup>10</sup>. Different approaches were successfully tested to improve curcumin oral absorption, including its conjugation with nanocarriers, such as phosphatidylserine phytosome or polyvinyl pyrrolidone-hydrophilic carrier, to obtain a curcumin formulation with a hydrophilic carrier (CHC, Diabec<sup>®</sup>, Alfa Intes, Italy). After CHC oral administration, a significantly high concentration of curcuminoids is present, *in vivo*, in blood and the retina<sup>8,11-13</sup>. This curcumin formulation is currently available on the Italian market.

Based on these findings, we conducted a study aimed at investigating the anti-inflammatory effectiveness and safety of oral CHC in addition to steroid standard therapy in subjects suffering from the recent onset of NIUME.

## Patients and Methods

### Study Design and Participants

This was a prospective observational study carried out between January 2019 and May 2020 on consecutive adult patients with a diagnosis of bilateral, recent-onset NIUME referred to the Ocular Inflammatory Diseases Center in Rapallo (Genoa, Italy). Uveitis was anatomically classified according to the Standardization of Uveitis Nomenclature (SUN) Working Group criteria<sup>14</sup>. Diabetic subjects, eyes operated for cataracts and eyes with other retinal complications (including alteration of retinal thickness) were excluded.

At enrollment, a detailed systemic and ocular history was collected. The patients' eyes underwent a complete ocular examination, including anterior and posterior segment slit-lamp examination, Goldmann applanation tonometry, Best Corrected Visual Acuity (BCVA) testing using 4-meter ETDRS (Early Treatment Diabetic Retinopathy Study) charts, SD-OCT (Optical Coherence Tomography; Heidelberg II Engineering GmbH, Heidelberg, Germany) and Optovue Angio-OCT (Optovue Inc., AngioVue, Fremont, CA, USA) imaging.

Patients were treated with standard therapy (oral steroids) or with a CHC add-on to standard treatment (one capsule *bis in die* of Diabec<sup>®</sup>), based on the physician's routine clinical practice. The standard therapy consisted of a starting dose of oral prednisone (1 mg/kg/day up to a maximum

50 mg/day dose) for 4 weeks, and then, tapered over 45 days to a 15 mg/day dose, which was maintained for 6 weeks and then tapered and discontinued in further 8 weeks.

Each CHC capsule contained 60 mg Curcumin<sup>®</sup> (dry powder 20% with a polyvinylpyrrolidone hydrophilic carrier). CHC treatment was performed for 6 months combined with systemic therapy and then continued alone for the other 6 months. The observation period for each patient was 12 months.

The study is conformed to Helsinki's Declaration and was approved by the Regional Ethical Committee and regulatory agency of Liguria (Italy) n° 247/18. All participants provided written informed consent.

### Study Measures

The study's primary aims were the evaluation of BCVA improvement (ETDRS charts) and Central Macular Thickness (CMT) reduction. Secondary endpoints were the foveal avascular zone (FAZ) area (Optovue AngioVue angiography) and the IOP variations.

All the above-mentioned parameters were evaluated at baseline ( $T_0$ ) and during each follow-up visit, carried out at 3 ( $T_3$ ), 6 ( $T_6$ ) and 12 ( $T_{12}$ ) months from the beginning of the treatment.

For the BCVA evaluation, the Snellen fraction of the ETDRS chart was converted to the logarithm of the minimum angle of resolution (logMAR) for statistical analysis and 0.02 logMAR units were given for each letter correctly identified on the entire chart.

The "Thickness Map" function of Heidelberg SD-OCT (center point thickness  $\geq 260$   $\mu\text{m}$ ) was used to automatically measure the mean CMT within a circular area of 0.5 mm radius from the foveal center. Macular edema was considered persistent or unresponsive to treatment when CMT was  $\geq 300$   $\mu\text{m}$ .

FAZ area calculation was performed on the superficial vascular retinal network using the nonflow function of the AngioAnalytics imaging software embedded in the Optovue AngioVue instrument. 6×6 mm scans of the superficial and deep capillary plexuses were collected for analysis; images were generated by automated layer segmentation, and, in case of wrong processing, manual segmentation was performed.

OCTA images were normalized to a standard window level based on the maximum and minimum intensity values to increase the reliability of the extracted features. The mean normal area was considered  $0.27 \pm 0.1$  mm<sup>2</sup> at the superficial network. Three

different OCTA biomarkers (FAZ area, contour irregularity and vessel density) were analyzed.

Two different observers evaluated SD-OCT and Angio-OCT images and excluded scans of poor quality. At each visit, any adverse effect was also registered.

### Statistical Analysis

Repeated measures analysis under the generalized linear mixed effect framework<sup>15</sup> was performed; in particular, the experimental design would model the responses as a function of treatment, time and their one-way interaction; following analyses with *post-hoc* means comparisons<sup>16</sup> to assess any statistical difference in the pairwise difference between specified time windows were performed. The R software was used for this purpose<sup>17</sup>, and statistical significance was evaluated using a 5% threshold.

## Results

### Study Population

A total of 26 consecutive patients (17 were females, mean±SD age was 53±4 years) were included in the study; 11 patients were treated with the standard therapy (control group) and 15 with the CHC add-on.

A total of 43 eyes out of 52 were included in the statistical analysis: nine eyes were excluded (4 in the control and 5 in the CHC group) because they were affected by retinal or optic disc atrophy with a CMT <300 µm (4 eyes), macular pucker (3 eyes) or dense vitreal opacities (2 eyes).

All patients presented intermediate or posterior uveitis. At the baseline, macular edema's mean (±SD) duration was 15 (±4) days from the onset.

The anatomic classification of uveitis according to the study group is summarized in Table I.

### BCVA Evaluations

The outcome was homogeneous at T<sub>0</sub> ( $p=0.482$ ). In the CHC group, a significant improvement of the mean BCVA was reported between T<sub>0</sub> and T<sub>6</sub> ( $0.34±0.05$  vs.  $0.20±0.02$ , respectively;  $p≤0.05$ ) and this improvement further increased at T<sub>12</sub> ( $0.19±0.02$ ;  $p≤0.01$ ), compared to T<sub>0</sub> evaluations.

The mean BCVA remains stable in the control group during the study period.

Statistical comparison between the two study groups showed a significant improvement of mean BCVA in the CHC group at T<sub>6</sub> and T<sub>12</sub> ( $p≤0.01$ ), compared to the control group (T<sub>6</sub>:  $0.20±0.02$  vs.  $0.37±0.06$ ; T<sub>12</sub>:  $0.19±0.02$  vs.  $0.40±0.07$ ).

### CMT Measurements

The outcome is homogeneous at T<sub>0</sub> ( $p=0.213$ ).

In the CHC group, the mean CMT significantly decreased from T<sub>0</sub> to T<sub>6</sub> ( $320.0±40.8$  vs.  $278.0±46.3$ ;  $p≤0.05$ ) and T<sub>12</sub> ( $272.0±51.9$ ;  $p≤0.01$ ) (Figures 1 and 2). Reduction corresponds to 14% at T<sub>6</sub> and 15% at T<sub>12</sub>, compared with baseline values

A trend towards the mean CMT reduction was observed in the control group, although not statistically significant (Figure 1).

### Secondary Outcomes

#### FAZ

The outcome was homogeneous at T<sub>0</sub> ( $p=0.928$ ). There is no significant change in the mean FAZ area. However, a trend towards restoring the normal architecture and perfusion of the perifoveal capillary net is mainly evident in the eyes of the CHC group (Figure 3).

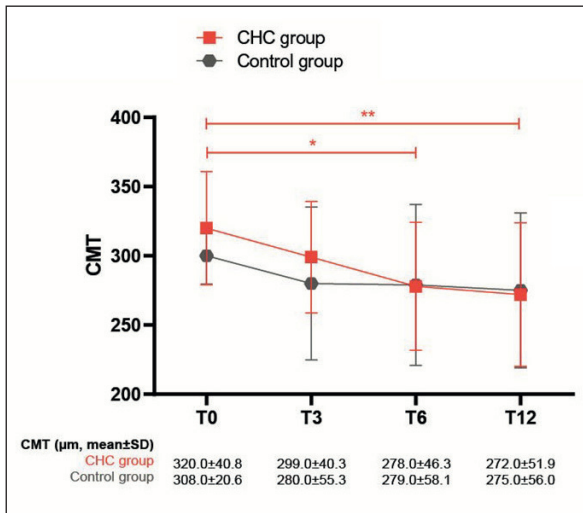
#### IOP

The outcome was homogeneous at T<sub>0</sub> ( $p=0.078$ ).

**Table I.** Anatomic classification of uveitis.

Type	Underlying pathology	CHC group (n)	Control group (n)	Total (n)
Panuveitis	Sarcoidosis	1	2	3
Posterior uveitis	Idiopathic uveitis	3	2	5
	Behçet disease	3	1	4
	Sarcoidosis	2	4	6
	Autoimmune retinal vasculitis	2	0	2
Intermediate uveitis	Idiopathic uveitis	2	0	2
	Multiple sclerosis	2	2	4
	<b>Total</b>	<b>15</b>	<b>11</b>	<b>26</b>

CHC: Curcumin formulation with the hydrophilic carrier.



**Figure 1.** Mean $\pm$ SD CMT measurements. CHC group shows a statistically significant improvement at T<sub>6</sub> ( $p \leq 0.05$ ) and T<sub>12</sub> ( $p \leq 0.01$ ), compared to baseline values (T<sub>0</sub>).

No clinically significant changes in mean pressure values were recorded for both groups. For the CHC group, a trend towards lower pressure mean values throughout the study period was observed (Figure 4).

**Safety Data**

No clinically significant adverse events were recorded during the study period; one patient only in the CHC group reported epigastric disturbances without a need for CHC discontinuation.

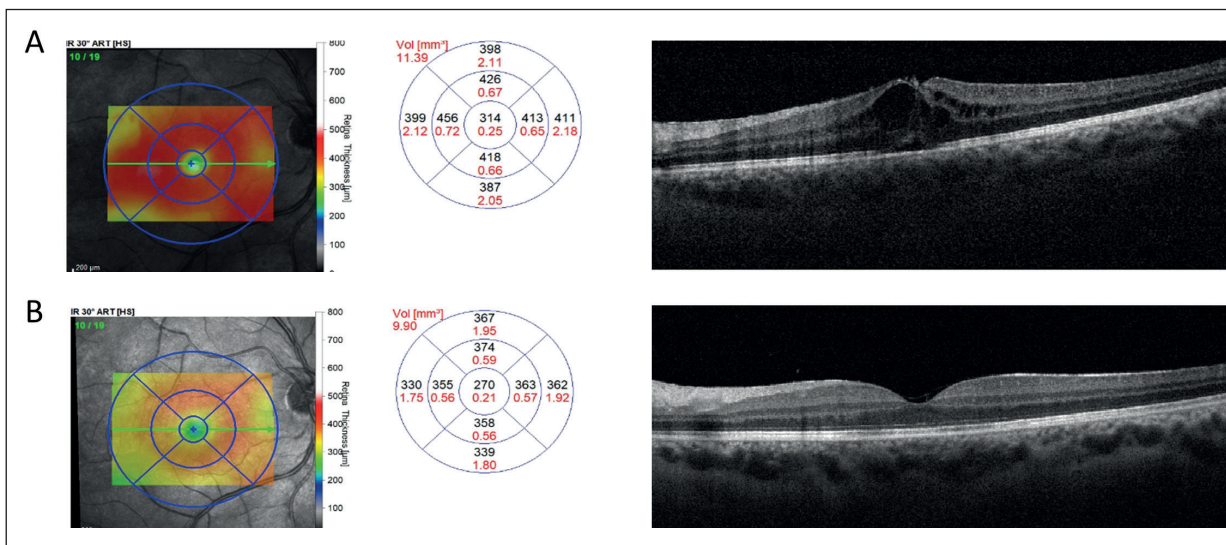
**Discussion**

UME is a common cause of visual loss in patients affected by intraocular inflammation, and it is a frequent complication of intermediate (25-70%) and posterior (19-34%) uveitis. However, it can also be seen in anterior uveitis. It frequently occurs in middle-aged or elderly subjects suffering from chronic forms of uveitis and can suddenly appear and recur along the disease course.

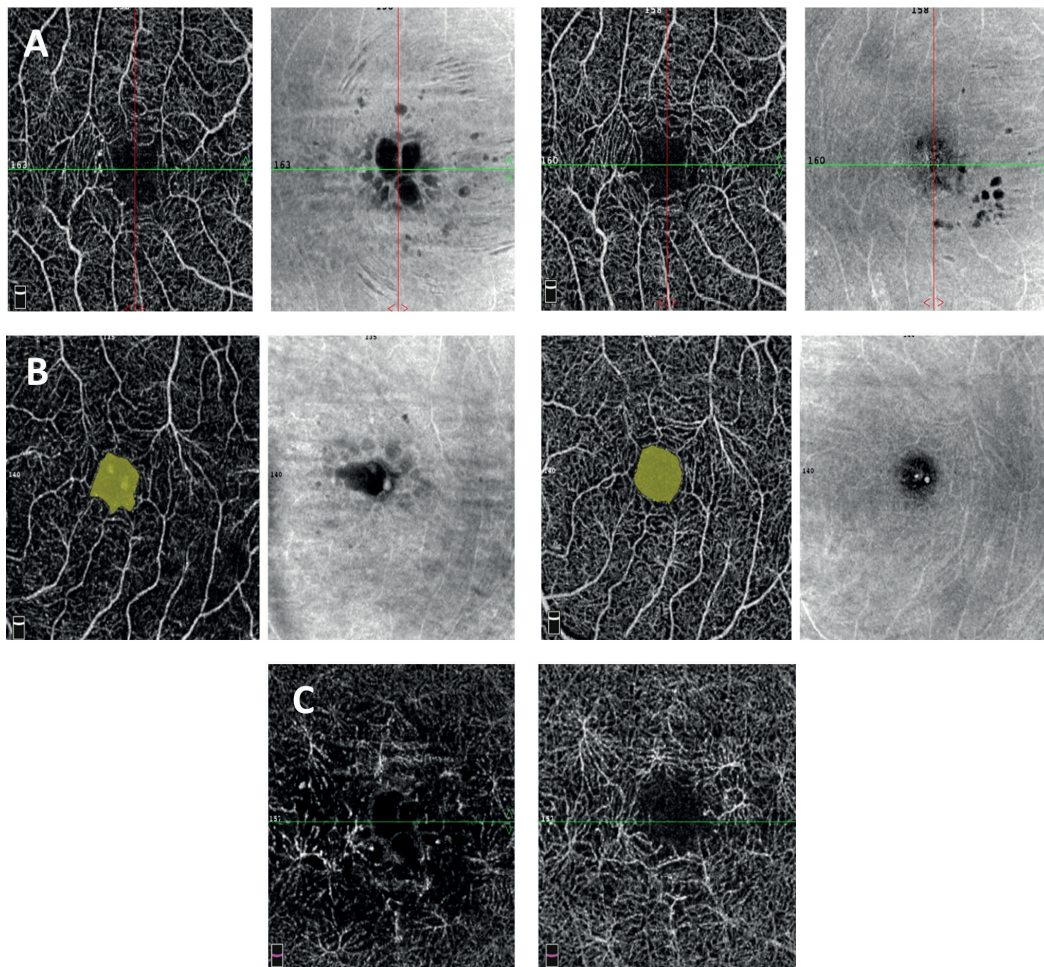
Different and independent factors may play a role in the pathogenesis of ME, mainly the breakdown of the inner and outer blood-retinal barrier produced by vasogenic and cytotoxic effects derived from inflammation (pro-inflammatory cytokines are delivered to the retina, namely prostaglandins, leukotrienes, protein kinase C, nitric oxide, TNF- $\alpha$ , interleukins, insulin-like growth factor and VEGF); different hypotheses have been postulated, including metabolic variations, toxic effects and hydrostatic forces on RPE and retinal capillaries, thus inducing an increased deposition of fluids, especially in the outer plexiform layer<sup>18-22</sup>. The endothelial damage due to leukocytes' adherence to vessel walls, the so-called "leukostasis", represents another co-factor in capillary wall injury<sup>23</sup>.

Prognostic factors, such as older age, low color or contrast sensitivity, long ME duration, and macular complications (ischemia, pucker or atrophy) are associated with visual impairment<sup>24,25</sup>.

First-line anti-inflammatory local treatment has a beneficial effect on recent-onset acute forms



**Figure 2.** Heidelberg SD OCT Thickness Map and Macula 30°. The right eye of a CHC-treated patient showing CMT thickness reduction from 314  $\mu\text{m}$  (A) to 270  $\mu\text{m}$  (B) at T<sub>0</sub> (A) and T<sub>12</sub> (B).

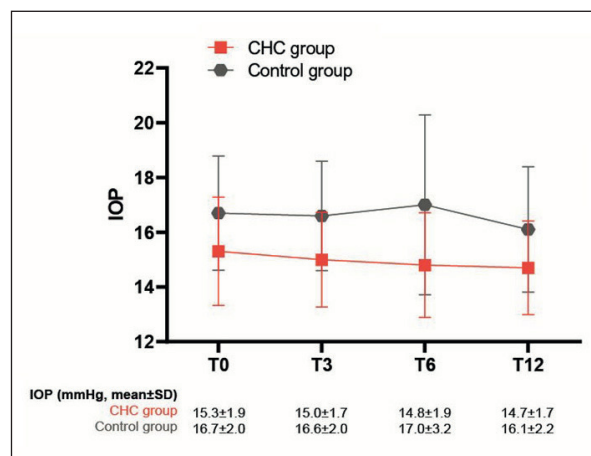


**Figure 3.** Optovue Angiovue Angio-OCT. FAZ superficial and deep capillary bed angiograms of the eyes of CHC-treated patients at  $T_0$  (a) and  $T_{12}$  (b). **A**, Some morphological variations in FAZ contour are evident. **B**, No significant variations of FAZ superficial and deep capillary bed area. **C**, Morphological changes are evident, showing a tendency towards normal round vascular perifoveal architecture.

of UME<sup>3</sup>. Corticosteroids inhibit the inflammatory mediator's cascade (i.e., arachidonic acid) and can delay the deterioration of endothelial tight-junctions and block the blood-retinal barrier permeability<sup>26,27</sup>.

Nevertheless, they have the potential for causing local or systemic adverse events. In addition, despite adequate control of the inflammatory activity, UME may persist after this first-line treatment. Consequently, an improvement of available therapies is a clinical need.

It has been previously analyzed the anti-inflammatory and immunomodulating effects of curcumin in the treatment of different retinal conditions. Indeed, curcumin can upregulate many factors involved in vessel wall damage and hyperpermeability and can downregulate the enzymatic activity of COX-2, NOS and other kinas-



**Figure 4.** IOP Outcome (mean±SD). No clinically significant variations along the follow-up period in both groups.

es by suppressing the transcription factor NF- $\kappa$ B. In addition, curcumin downregulates the expression of pro-inflammatory cytokines (ILs, TNF- $\alpha$ ) and proteins (MCP and MIP). It also inhibits the VEGF release, which downregulates vascular permeability and retinal neo-angiogenesis. Müller cells and activated microglial cells take part in this process<sup>20,28-36</sup>. Lastly, it has been demonstrated that the activation of the PPAR- $\gamma$ 31 mediates the anti-inflammatory activity of curcumin.

Different approaches have been proposed to enhance curcumin absorption, bioavailability and stability, such as 1) integration of curcumin in different systems (nanoparticles, copolymers, micelles, exosomes, cyclodextrins and hydrogels); 2) pro-drugs; 3) complexation with other substances (piperine and phospholipids, such as phyto-somes); and 4) combination with a polyvinyl-pyrrolidone-hydrophilic carrier (CHC, Diabec<sup>®</sup>)<sup>37-45</sup>.

CHC oral administration showed a significantly enhanced plasma and retinal concentration of active curcuminoids<sup>33,45,46</sup>. Ferrara et al<sup>47</sup> studied oral CHC efficacy to treat post-operative ME and chronic-CSC; statistically significant results in improving visual acuity (VA) and SD-OCT findings, without any side effects, and a global complete resolution of ME in the 74% of cases were obtained.

Functional and anatomical evaluation on the effectiveness and safety of CHC as an add-on therapy to standard therapy to treat NIUME were the objectives of the present observational study.

Improvements in BCVA and CMT were the primary targets of the study and were observed at 6- and 12-months follow-up visits in the CHC group.

CMT showed no statistical evidence in the control group, even if a trend in CMT improvement was detected. Statistical comparison between the two groups showed significant results ( $p \leq 0.01$ ) favoring CHC treatment considering BCVA at T<sub>6</sub> and T<sub>12</sub>. This suggests that rapidly decreasing oxidative stress and delivery of toxic molecules may result in a faster reduction of damage to retinal cells and vessels. Unexpectedly, the BCVA remains stable in the standard treatment group over the study period. This could be caused by the greater number of patients affected by sarcoidosis in the control group (Table I). It is possible that these patients had a greater degree of impairment of the optic nerve and retina than patients in the CHC group. Thus, this aspect needs to be verified in an additional trial with a larger number of patients<sup>48</sup>.

Disorganization of the retinal layers with a larger FAZ (which also correlates with lower VA) was seen at T<sub>0</sub> and T<sub>12</sub> in most of the enrolled patients, despite a resolved UME.

Persistent damage to perifoveal area microvasculature may explain abnormal VA at T<sub>12</sub>, although a complete recovery in CMT was achieved.

Mean FAZ area at superficial vessels layer was  $0.31 \pm 0.3$  mm<sup>2</sup> in both groups at baseline, whereas  $0.328$  mm<sup>2</sup> plus abnormal vessel density and shape after 12 months ( $p=0.1$ ). However, an aspect towards normal round vascular perifoveal architecture was mainly seen in CHC eyes. This was probably due to a re-perfusion attempt<sup>49,50</sup>. IOP variations were not clinically nor statistically significant throughout the study period ( $p=0.16$ ).

Any adverse effect was reported. Although liver toxicity may be present in some sensitive subjects<sup>38</sup>, our patients did not show any systemic intolerance (except for gastric low tolerability of one patient) along the study period.

None of the enrolled patients presented a ME relapse. This is somewhat surprising if we consider that, following recent literature<sup>51,52</sup>, ME relapses are frequent in a mean period of 6 months. We suppose that: a) lots of them suffered from systemic autoimmune diseases, which can be successfully treated with oral steroids; b) acute onset ME (mainly of the diffuse type) is more responsive to therapy; c) patients showed high treatment compliance because the COVID-19 lockdown forced them to stay at home and correctly take their medications. For instance, during the COVID-19 lockdown, the Ocular Inflammatory Diseases Center in Rapallo continued its routine activities, and patients regularly underwent periodic visits.

## Conclusions

UME is currently a therapeutic challenge, and aggressive systemic treatment is frequently required at disease onset. Even if this study presents some limitations, as the observational nature and the reduced number of patients, to the best of our knowledge, this is the first study concerning CHC therapeutic activity on acute onset NIUME. It showed that a CHC adjunctive-to-reference treatment might result in a faster anatomical and functional improvement than the sole systemic treatment, which may be maintained once reference therapy is discontinued. Further studies analyzing a greater number of subjects with recent-onset NIUME are therefore guaranteed.

## Acknowledgments

The authors would like to thank prof. Ilknur Tugal Tutkun (Uveitis Center, Istanbul University Eye Clinic) for the fundamental scientific support and Dr. Anna Rita Blanco (Medical Scientific Liaison, Alfa Intes) for the collaboration. Editorial assistance was provided by Simonetta Papa, PhD, and Aashni Shah (Polistudium SRL, Milan, Italy). Graphical assistance was provided by Massimiliano Pianta (Polistudium SRL, Milan, Italy). This assistance was supported by Alfa Intes.

## Conflict of Interests

No funding was received for this work. The authors declare that there are no conflicts of interests regarding the publication of this paper. They have no financial interest in any of the products mentioned in the article.

## Authors' Contributions

Designed the study: Allegri Pia. Conducted the study: Allegri Pia, Rosa Raffaella, Masala Alessandro  
Analyzed/interpreted data: All. Provided materials: Allegri Pia. Wrote the article: Allegri Pia, Rissotto Roberta, Rissotto Federico. Proofed/revised article: All authors.

## References

- 1) Dick AD. The treatment of chronic uveitic macular oedema. *Br J Ophthalmol* 1994; 78: 1-2.
- 2) Adán A, Moll-Udina A, Alba-Linero C, Figueroa-Verrellino JP, Llorenç V. Recent progress in the treatment of uveitic macular edema. *Expert Rev Ophthalmol* 2019; 14: 227-236.
- 3) Koronis S, Stavrakas P, Balidis M, Kozeis N, Tranos PG. Update in treatment of uveitic macular edema. *Drug Des Devel Ther* 2019; 13: 667-680.
- 4) Ossewaarde-van Norel A, Rothova A. Clinical review: Update on treatment of inflammatory macular edema. *Ocul Immunol Inflamm* 2011; 19: 75-83.
- 5) Accorinti M, Okada AA, Smith JR, Gilardi M. Epidemiology of macular edema in uveitis. *Ocul Immunol Inflamm* 2019; 27: 169-180.
- 6) Rothova A. Inflammatory cystoid macular edema. *Curr Opin Ophthalmol* 2007; 18: 487-492.
- 7) Lardenoye CW, van Kooij B, Rothova A. Impact of macular edema on visual acuity in uveitis. *Ophthalmology* 2006; 113: 1446-1449.
- 8) Platania CBM, Fidilio A, Lazzara F, Piazza C, Geraci F, Giurdanella G, Leggio GM, Salomone S, Drago F, Bucolo C. Retinal protection and distribution of curcumin in vitro and in vivo. *Front Pharmacol* 2018; 9: 670.
- 9) Farajipour H, Rahimian S, Taghizadeh M. Curcumin: A new candidate for retinal disease therapy? *J Cell Biochem* 2018. Online ahead of print. <https://doi.org/10.1002/jcb.28068>
- 10) Ullah F, Liang A, Rangel A, Gyengesi E, Niedermayer G, Münch G. High bioavailability curcumin: an anti-inflammatory and neurosupportive bioactive nutrient for neurodegenerative diseases characterized by chronic neuroinflammation. *Arch Toxicol* 2017; 91: 1623-1634.
- 11) Jäger R, Lowery RP, Calvanese AV, Joy JM, Purpura M, Wilson JM. Comparative absorption of curcumin formulations. *Nutr J* 2014; 13: 11.
- 12) Anand P, Kunnumakkara AB, Newman RA, Aggarwal BB. Bioavailability of curcumin: problems and promises. *Mol Pharm* 2007; 4: 807-818.
- 13) López-Malo D, Villarón-Casares CA, Alarcón-Jiménez J, Miranda M, Díaz-Llopis M, Romero FJ, Villar VM. Curcumin as a therapeutic option in retinal diseases. *Antioxidants (Basel)* 2020; 9: 48.
- 14) Jabs DA, Nussenblatt RB, Rosenbaum JT; Standardization of Uveitis Nomenclature (SUN) Working Group. Standardization of uveitis nomenclature for reporting clinical data. Results of the First International Workshop. *Am J Ophthalmol* 2005; 140: 509-516.
- 15) Douglas B, Mächler M, Bolker B, Walker S. Fitting linear mixed-effects models using lme4. *J Stat Software* 2015; 67: 1-48.
- 16) Length R, 2019. Emmeans: Estimated Marginal Means, Aka Least-Squares Means. Available at: <https://CRAN.R-project.org/package=emmeans>.
- 17) R Core Team, 2019. R: A Language and Environment for Statistical Computing. Vienna, Austria: R Foundation for Statistical Computing. Available at: <https://www.R-project.org/>.
- 18) Fardeau C, Champion E, Massamba N, LeHoang P. Uveitic macular edema. *Eye (Lond)* 2016; 30: 1277-1292.
- 19) Cho H, Madu A. Etiology and treatment of the inflammatory causes of cystoid macular edema. *J Inflamm Res* 2009; 2: 37-43.
- 20) Massa H, Pipis SY, Adewoyin T, Vergados A, Patra S, Panos GD. Macular edema associated with non-infectious uveitis: pathophysiology, etiology, prevalence, impact and management challenges. *Clin Ophthalmol* 2019; 13: 1761-1777.
- 21) Agarwal A, Pichi F, Invernizzi A, Gupta V. Disease of the year: differential diagnosis of uveitic macular edema. *Ocular Immunol Inflammation* 2019; 27: 72-88.
- 22) Johnson MW. Etiology and treatment of macular edema. *Am J Ophthalmol* 2009; 147: 11-21.e1.
- 23) Leal EC, Manivannan A, Hosoya K, Terasaki T, Cunha-Vaz J, Ambrósio AF, Forrester JV. Inducible nitric oxide synthase isoform is a key mediator of leukostasis and blood-retinal barrier breakdown in diabetic retinopathy. *Invest Ophthalmol Vis Sci* 2007; 48: 5257-5265.
- 24) Durrani OM, Tehrani NN, Marr JE, Moradi P, Stavrou P, Murray PI. Degree, duration, and causes of visual loss in uveitis. *Br J Ophthalmol* 2004; 88: 1159-1162.
- 25) Guex-Crosier Y. The pathogenesis and clinical presentation of macular edema in inflammatory diseases. *Doc Ophthalmol* 1999; 97: 297-309.
- 26) Goldhardt R, Rosen BS. Uveitic macular edema: treatment update. *Curr Ophthalmol Rep* 2016; 4: 30-37.
- 27) Taylor SR, Lightman SL, Sugar EA, Jaffe GJ, Freeman WR, Altaweel MM, Kozak I, Holbrook JT, Jabs DA, Kempen JH. The impact of macular edema on visual function in intermediate, posterior, and panuveitis. *Ocul Immunol Inflamm* 2012; 20: 171-181.

- 28) Muangnoi C, Sharif U, Ratnatilaka Na Bhuket P, Rojsitthisak P, Paraoan L. Protective effects of curcumin ester prodrug, curcumin diethyl disuccinate against H<sub>2</sub>O<sub>2</sub>-induced oxidative stress in human retinal pigment epithelial cells: potential therapeutic avenues for age-related macular degeneration. *Int J Mol Sci* 2019; 20: 3367.
- 29) López-Malo D, Villarón-Casares CA, Alarcón-Jiménez J, Miranda M, Díaz-Llopis M, Romero FJ, Villar VM. Curcumin as a therapeutic option in retinal diseases. *Antioxidants (Basel)* 2020; 9: 48.
- 30) Gupta SK, Agarwal R, Srivastava S, Agarwal P, Agrawal SS, Saxena R, Galpalli N. The anti-inflammatory effects of *Curcuma longa* and *Berberis aristata* in endotoxin-induced uveitis in rabbits. *Invest Ophthalmol Vis Sci* 2008; 49: 4036-4040.
- 31) Pescosolido N, Giannotti R, Plateroti AM, Pascarella A, Nebbioso M. Curcumin: therapeutic potential in ophthalmology. *Planta Med* 2014; 80: 249-254.
- 32) Jamwal R. Bioavailable curcumin formulations: A review of pharmacokinetic studies in healthy volunteers. *J Integr Med* 2018; 16: 367-374.
- 33) Peddada KV, Brown A, Verma V, Nebbioso M. Therapeutic potential of curcumin in major retinal pathologies. *Int Ophthalmol* 2019; 39: 725-734.
- 34) Granata G, Paterniti I, Geraci C, Cunsolo F, Esposito E, Cordaro M, Blanco AR, Cuzzocrea S, Consoli GML. Potential eye drop based on a calix[4]arene nanoassembly for curcumin delivery: enhanced drug solubility, stability, and anti-inflammatory effect. *Mol Pharm* 2017; 14: 1610-1622.
- 35) Pittalà V, Salerno L, Fidilio A, Lazzara F, Platania CBM, Drago F, Bucolo C, Foresti R. Effects of novel nitric oxide-releasing molecules against oxidative stress on retinal pigmented epithelial cells. *Oxidative Med Cell Longev* 2017; 2017: 1420892.
- 36) Mazzolani F, Togni S. Oral administration of a curcumin-phospholipid delivery system for the treatment of central serous chorioretinopathy: a 12-month follow-up study. *Clin Ophthalmol* 2013; 7: 939-945.
- 37) Liu XF, Hao JL, Xie T, Mukhtar NJ, Zhang W, Malik TH, Lu CW, Zhou DD. Curcumin, A Potential Therapeutic Candidate for Anterior Segment Eye Diseases: A Review. *Front Pharmacol* 2017; 8: 66.
- 38) Wang LL, Sun Y, Huang K, Zheng L. Curcumin, a potential therapeutic candidate for retinal diseases. *Mol Nutr Food Res* 2013; 57: 1557-1568.
- 39) Salehi B, Stojanović-Radić Z, Matejić J, Sharifi-Rad M, Anil Kumar NV, Martins N, Sharifi-Rad J. The therapeutic potential of curcumin: A review of clinical trials. *Eur J Med Chem* 2019; 163: 527-545.
- 40) Aggarwal BB, Harikumar KB. Potential therapeutic effects of curcumin, the anti-inflammatory agent, against neurodegenerative, cardiovascular, pulmonary, metabolic, autoimmune and neoplastic diseases. *Int J Biochem Cell Biol* 2009; 41: 40-59.
- 41) Wang J, Wang F, Li F, Zhang W, Shen Y, Zhou D, Guo S. A multifunctional poly(curcumin) nanomedicine for dual-modal targeted delivery, intracellular responsive release, dual-drug treatment and imaging of multidrug resistant cancer cells. *J Mater Chem B* 2016; 4: 2954-2962.
- 42) Danafar H, Davaran S, Rostamizadeh K, Valizadeh H, Hamidi M. Biodegradable m-PEG/PCL core-shell micelles: Preparation and characterization as a sustained release formulation for curcumin. *Adv Pharm Bull* 2014; 4: 501-510.
- 43) Zs. Nagy N, Varga Z, Mihály J, Kasza G, Iván B. Kiss Highly efficient encapsulation of curcumin into and pH-controlled drug release from poly( $\epsilon$ -caprolactone) nanoparticles stabilized with a novel amphiphilic hyperbranched polyglycerol. *Express Polym Lett* 2020; 14: 90-101.
- 44) Kumari P, Muddineti OS, Rompicharla SVK, Ghanta P, Adithya KBBN, Ghosh B, Biswas S. Cholesterol-conjugated poly(D, L-lactide)-based micelles as a nanocarrier system for effective delivery of curcumin in cancer therapy. *Drug Deliv* 2017; 24: 209-223.
- 45) Allegri P, Mastromarino A, Neri P. Management of chronic anterior uveitis relapses: efficacy of oral phospholipidic curcumin treatment . Long-term follow-up. *Clin Ophthalmol* 2010; 4: 1201-1254.
- 46) López-Malo D, Villarón-Casares CA, Alarcón-Jiménez J, Miranda M, Díaz-Llopis M, Romero FJ, Villar VM. Curcumin as a therapeutic option in retinal diseases. *Antioxidants (Basel)* 2020; 9: 48.
- 47) Ferrara M, Allegrini D, Sorrentino T, Sborgia G, Parmeggiani F, Borgia A, Romano MR. Curcumin-based treatment for macular edema from uncommon etiologies: efficacy and safety assessment. *J Med Food* 2020; 23: 834-840.
- 48) Matsou A, Tsaousis KT. Management of chronic ocular sarcoidosis: challenges and solutions. *Clin Ophthalmol* 2018; 12: 519-532.
- 49) Khochtali S, Tugal-Tutkun I, Fardeau C, Maestri F, Khairallah M. Multimodality approach to the diagnosis and assessment of uveitic macular edema. *Ocular Immunol Inflammation* 2020; 28: 1212-1222.
- 50) AttaAllah HR, Mohamed AAM, Ali MA. Macular vessels density in diabetic retinopathy: quantitative assessment using optical coherence tomography angiography. *Int Ophthalmol* 2019; 39: 1845-1859.
- 51) Nobre-Cardoso J, Champion E, Darugar A, Fel A, Lehoang P, Bodaghi B. Treatment of non-infectious uveitic macular edema with the intravitreal dexamethasone implant. *Ocul Immunol Inflamm* 2017; 25: 447-454.
- 52) Tsang AC, Virgili G, Abtahi M, Gottlieb CC. Intravitreal Dexamethasone Implant for the Treatment of Macular Edema in Chronic Non-infectious Uveitis. *Ocul Immunol Inflamm* 2017; 25: 685-692.